

303. Surgical treatment of equinus foot deformity in cerebral palsy patients

L. Sycheuski

Grodno State Medical University, Grodno Emergency Hospital, Pediatrics Orthopaedics Department,
ul Sovietskih Pogranichnikov 115, 230027 Grodno, Belarus
Phone: (+375)152-500-530, fax: (+375)152-500-554
E-mail: leosych@gmail.com

(Received 06 June 2007, accepted 12 September)

Abstract. Since 1997 thirty seven spastic cerebral palsy children (54 feet) with shortening m. triceps surae (soleus and gastrocnemius portions) underwent heel cord advancement by simplified technique of Murphy procedure. Good correction of the deformity and gait improvement was obtained in 52 cases (96%). No patient had a recurrence of equines. All patients and his parents are satisfied with results of treatment. It study has documented that heel cord advancement is biomechanically- and pathophysiologically- grounded procedure for adequate correction and following prevention of equinus deformity. Proposed technique of heel cord advancement is relatively simple minimal invasive and can use for treatment as single or(and) with combination in multilevel operations. Best results of surgical treatment obtained in young child who has non-formed rigid deformation and has no stable pathological gait patterns yet.

Keywords: Cerebral palsy, equines foot deformity, heel cord advancement.

Introduction

Spastic equinus is most common deformity in patient with cerebral palsy [1]. Numerous procedures have been described for treatment of spastic equines deformity. In patients with shortening only m. gastrocnemius the results of different gastrocnemius recessing procedures (Strayer, Vulpius, Baker, Tachdjian procedures) have been satisfactory [1], [2], [5], [8], [12]. In cases with shortening both portions of m. triceps surae (gastrocnemius and soleus) the results of Achilles tendon lengthening alone or in combination with recessing are disappointing with unstable, crouch gait [6], [11], [15]. Selective neurectomy is passe' because fibrotic, contracted muscles are often result [4]. The gastrocnemius and soleus has distinctly different functions during gait. The gastrocnemius muscle is a fast-twitch, precisely timed muscle that is responsible for the coordinated movement of knee and ankle. The soleus is a slow-twitch, stance-phase eccentric stabilizer that is primarily responsible for maintaining the integrity of the normal plantar flexion\knee extension (PF\KE) couple during mid-stance which provides about half of the total support needed for upright posture[6], [9], [15] (Fig.1). Muscle-length model indicate that the soleus is extremely sensitive to lengthening (Delp. et al. 1995). It has been shown by these models that a 1 cm lengthening of the soleus will lead to a 50% loss of the force-generating capacity of the muscle because of a lengthening of the

tendon distal to the muscle belly of the soleus leads to a more horizontal orientation of the muscle fibers of the bipennate soleus. In addition, muscle with short muscle-fiber lengths are much more sensitive to lengthening than those with long fiber lengths due to the fact that the percentage change in resting muscle-fiber length is much greater[3] (Fig. 2).

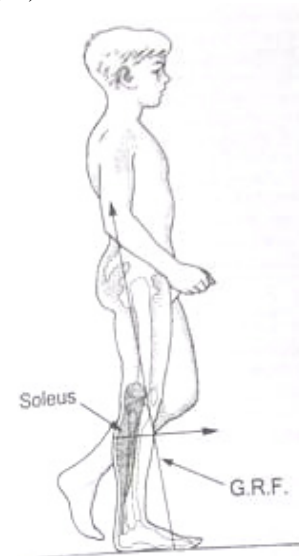


Fig. 1. Plantar flexion\knee extension couple generating during mid-stance

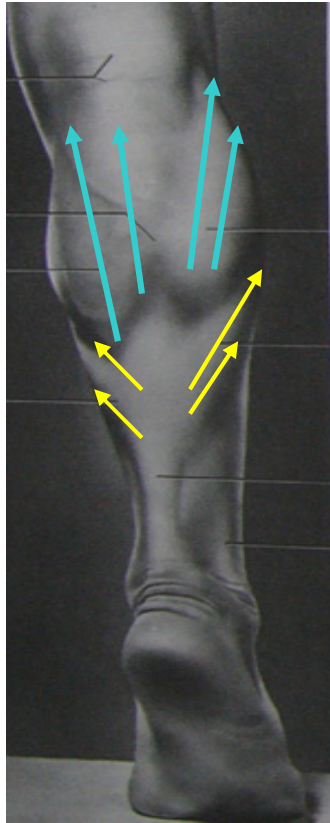


Fig. 2. The Difference of Fibers Orientation and Length Between Gastrocnemius and Soleus.

Therefore lengthening of the heel-cord in the ambulatory patient should be avoided, because there seems to be no appropriate length for Achilles tendon lengthening.

Pierrot and Murphy devised heel cord advancement as an alternative to the lengthening procedure [10]. By shortening the length of the calcaneal lever arm, the effect of the triceps surae is decreased. More over, after anterior advancement of the heel cord on the calcaneus, plantarflexion force would be reduced by 48%, while the detrimental reduction to push off power would be reduced by only 15% (Fig.3).

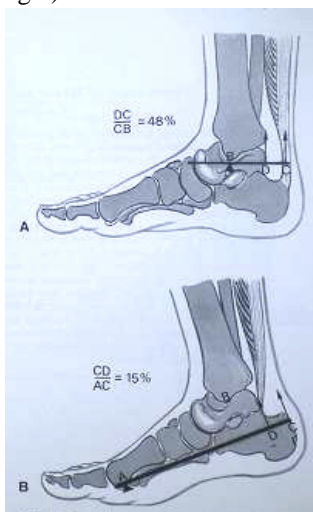


Fig. 3. The Principle of Anterior Advancement of the Heel Cord

However owing to relative complicity and invasiveness this procedure it doesn't find acceptance in the midst of orthopedic surgeons (Fig.4).

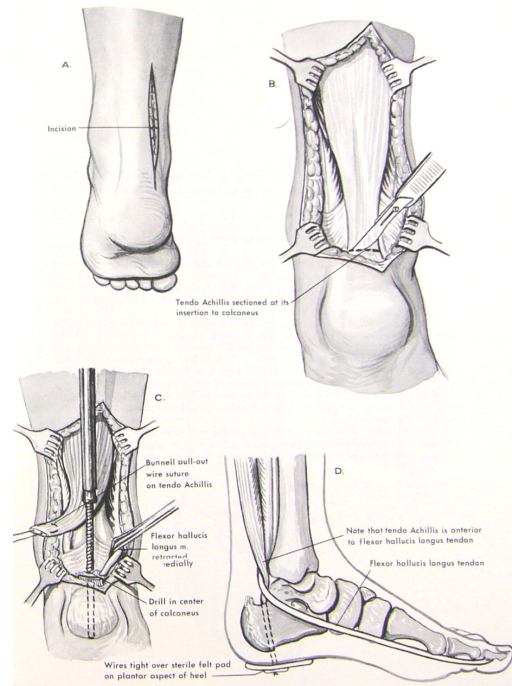


Fig. 4. Anterior Advancement of Tendo Acillis by Murphy Technique.

Since 1997, heel cord advancement by simplified, less invasive technique has been performed on 37 patients at our hospital.

Materials and methods

Operation procedure. The patients were positioned prone on the operating table after administration of general anesthesia. Tourniquets were used. Short 2-2.5 cm transverse incision like small Cincinnati was made to expose the Achilles tendon (Fig.5).

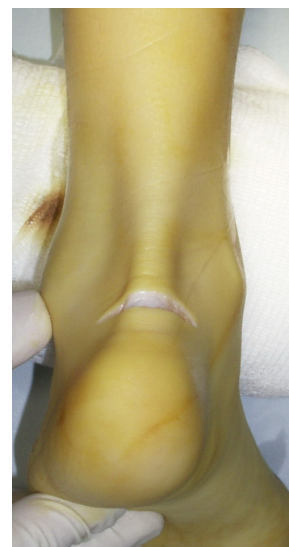

Fig. 5. Incision.

Achilles tendon was cut off from calcaneal as distally as possible, didn't divide from sheath and mobilized proximally.

Two non-absorbable suture №3 was passed through the both sides of Achilles tendon in a Kessler-like fashion. Starting posterior to the subtalar joint, we cut down groove by knife (in patients before 8 y.o.), or chisel (in patients after 8 y.o.).(Fig.6).

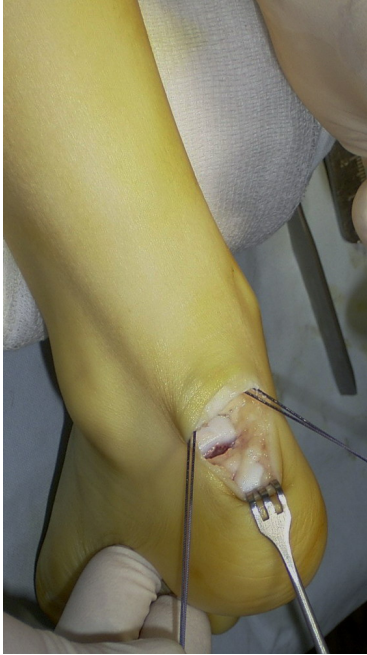

Fig. 6. Groove and Suture

The tendon was reinserted into the groove by steeply curved needle in 4 points easy since cancellous calcaneal bone is soft in this place (Fig.7 and 8). A suture was knotted on cortical plate in two knot whereby strong fixation and good adaptation was created.

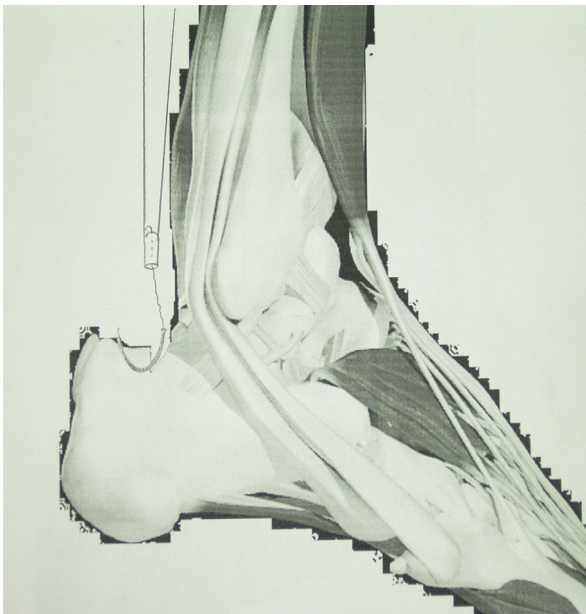


Fig. 7. Pricking

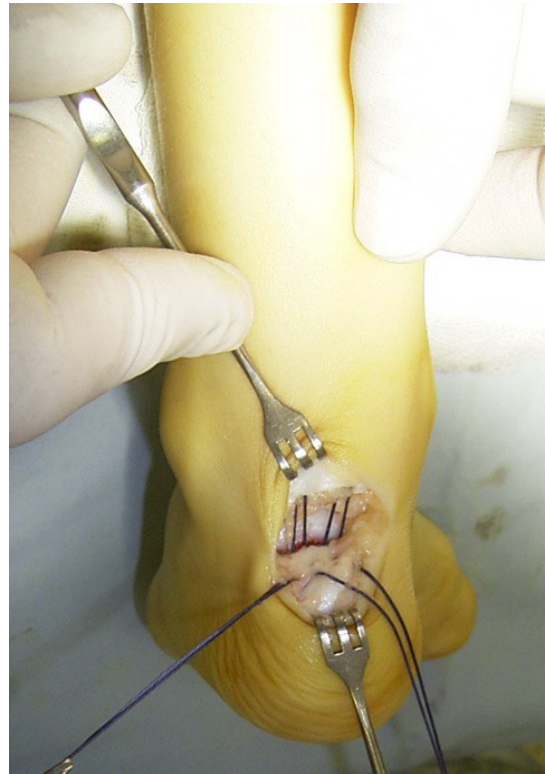

Fig. 8. Reinsertion

In case neutral position was not achieved muscle recession by Strayer or Vulpeus was performed from small additional approach. Split plaster cast was applied for 6 weeks.

Orthosis, orthopedics devices and special shoes was recommended in future.

All of patients was admitted on department after 6 weeks for rehabilitation course and examined every year by operating surgeon.

Thirty seven spastic cerebral palsy children (54 feet) with shortening m. triceps surae (soleus and gastrocnemius portions) underwent heel cord advancement by technique described above.

The mean age at operation was 6 years 8 month (range 3-14 years).The majority of the patients had spastic diplegia 63 %, 32% had spastic hemiplegia, and the remaining 5 % had spastic quadriplegia. The average follow-up was 3 years 10 month, ranging from 3 month to 8 years. All patients underwent heel cord advancement procedures. In addition, 6 patients underwent concomitant Strayer procedures. In 4 patients heel cord advancement was performed with his 1,5-2,5cm Z-plasty lengthening. In 7 cases with equinovarus foot deformity split posterior tibial tendon transfer or split anterior tibial tendon transfer or intramuscular posterior tibial tendon tenotomy was performed additionally. In 23 cases heel cord advancement was performed simultaneously in multilevel interventions.

Patient data were collected in regard to the type of cerebral palsy, pre- and postoperative gait, ambulatory status, and range of motion assessment. Ambulatory status and requirements in assistive devices and orthosis was divided into five groups: 1- nonambulatory, 2 – independent with assistive device and orthosis, 3 – independent with assistive device but no orthosis, 4 – independent with orthosis but without assistive device, 5– independent ambulation.

Range of walking abilities was assessed by Gillette Functional Assessment Questionnaire: Functional Walking Scale [16] and divided into ten groups: 1 – Cannot take any steps at all, 2 – Can do some stepping on his \her own with the help of another person. Does not take full weight on feet; does not walk on a routine basis; 3 – Walks for exercises in therapy and less than typical household distances. Usually requires assistance from another person; 4 – Walks for household distances, but makes slow progress, does not use walking at home as preferred mobility (primarily walks in therapy); 5 - Walks more than 15-50 feet outside the home or school (walks for household distances). 6 - Walks more than 15-50 feet outside the home, but usually uses a wheelchair or stroller for community distances or in congested areas; 7 - Walks outside the home for community distances, but only on level surfaces (cannot perform curbs, uneven terrain, or stairs without assistance of another person); 8 - Walks outside the home for community distances, is able to perform curbs and uneven terrain in addition to level surfaces, but usually requires minimal assistance or supervision for safety; 9 - Walks outside the home for community distances, easily gets around on level ground, curbs, and uneven terrain, but has difficulty or requires minimal assistance with running, climbing, and\or stairs; 10 -walks , runs, and climbs on level and uneven terrain without difficulty or assistance

Preoperative gait was characterized as equinus or equinovarus gait, flatfoot type gait, gait with knee hyperextension. Postoperative gait was classified as equines or equinovarus gait, plantigrade gait with decreased push off and heel-toe gait with good push off.

A questionnaire about foot function and patient satisfaction was answered by the patients or by their caregivers. The questionnaire included six categories: comfort of wearing shoes, foot pain, effect on ambulation, ambulation status in the house, ambulation status in the community, and the willingness to recommend this operation.

Results and discussion

Thirty two percent of our study group patients were independent ambulators preoperatively without use of assistance or orthotics (group 5). The remaining 68% were essentially divided between limited ambulators requiring assistive devices or orthosis and nonambulators. Postoperatively, the number of independent ambulators improved to 86%. 11 percent of patients required assistive devices, and 3% required both assistive devices and

orthosis. However no patients remained nonambulatory, and no patient demonstrated a decrease in function (Table 1).

Table 1. Number of patients in each ambulatory status group before and after heel cord advancement

Preoperative group	Postoperative group				
	1	2	3	4	5
1	0	1	3	0	0
2	0	0	1	2	0
3	0	0	0	8	10
4	0	0	0	0	7
5	0	0	0	0	5

Improvement of physical function and mobility is the goal of surgical treatment for children with developmental disability such as cerebral palsy. Four patients from group exercise ambulation levels (3 and 4) raised to household or classroom walking level (5) – 3%, limited community walking level (6) – 5% and routine community walking on level surface (7) – 3%. Eight household or classroom walking patients passed to limited walking – 3%, routine community walking on level surface – 3%, more advanced levels of walking on a variety of terrains (8 and 9) – 16%. Four patients with routine community walking on level surface before operation passed to more advanced levels of walking on a variety of terrains -8% and typical, nondisabled level of walking ability (10) - 3%. Five patients (14%), from advanced levels of walking on a variety of terrains still more improved his walking and functional ability after operation. Three patients (8%) didn't change his walking and functional ability after operation.(Table 2).

Table 2. Gillette Functional Assessment Questionnaire

Preoperative group	Postoperative group									
	1	2	3	4	5	6	7	8	9	10
1			1							
2				2	1					
3					1					
4						2	1			
5						1	1	3	3	
6							1	3	5	
7								1	2	1
8								1	1	1
9									1	3
10										1

The improvement in gait with heel cord advancement was pronounced. Preoperatively, 87% of the patients were toe walkers; postoperatively, 75% demonstrated a heel-toe gait and 20% had a plantigrade gait.

A questionnaire about foot function and patient satisfaction: 41% patient and their caregivers assessed the results as excellent, 56% as good, 3% was more or less satisfied. Many patients didn't use orthosis and orthopedics

devices because of social and domestic problems. Nevertheless decreasing of walking and functional abilities, gait problems and recurrence of deformity were not observed in these patients.

Four patients were undergone USG investigation after 2, 6, 12 month after operation and 1 patient were undergone MRI of Achilles tendon zone. There were no heel cord migrations in these observations. Therefore we suggest there no need to routing of heel cord anterior to the flexor hallucis longus for prevention of reattaching to its original insertion on tubercle of calcaneus as supposed by Murphy and other authors. This detail makes the operation more difficult and invasive. We recommend just don't divide Achilles tendon from its sheath after detaching.

Strongly pronounced improving of gait and function was founded in young patients (younger then 8 y.o.) and patients with nonsevere cases of cerebral palsy.

Therefore, almost in all patients a good results were obtained, that correspond with Throop et al.[14], Strecker et al.[13], whose achieved 90% and 98% good results accordingly after similar, but more complicated and invasive operative technique.

The effects of multilevel surgery and improvement of function at other joints undoubtedly influences the results.

We rarely use methods of lengthening of the triceps surae for equines deformity and do not have sufficient data for a comparative study.

Conclusions

The goal in performing surgery for equines and spasticity is to correct equines and reduce spasticity so that the ankle and knee can function more normally. Heel cord advancement is biomechanically- and pathophysiologically-grounded procedure for adequate correction, following prevention of equinus deformity, improving of walking and functional ability in cerebral palsy patients.

Proposed technique of heel cord advancement is relatively simple, minimal invasive and can use for treatment as single or (and) with combination in multilevel operations.

Best results of surgical treatment obtained in young child who has non-formed rigid deformation and has no stable pathological gait patterns yet.

As a result of this study we would recommend heel cord advancement procedure in our modification for fixed equines contractures in cerebral palsy.

References

- [1] **Banks H. H., Green W. T.** The correction of equines deformity in cerebral palsy. *The Journal of Bone and Joint Surgery* [Am] 1958; 40: 1359-79.
- [2] **Banks H. H.** The management of spastic deformities of the foot and ankle. *Clinical Orthopaedics* 1977; 122: 70-5.
- [3] **Delp S. L., Zajac F. E.** Force- and moment-generating capacity of lower-extremity muscles before and after tendon lengthening. *Clinical Orthopaedics and Related Research*. 1992; 284:247-59.
- [4] **Graig J. J., Van Vuren J.** The importance of gastrocnemius recession in the correction of equines deformity in cerebral palsy. *Journal of Bone and Joint Surgery* [Br] 1976; 58: 84 -7.
- [5] **Makley J. T., Kim W. C.** *Spastic equines deformities. Comprehensive management of cerebral palsy.* New York: Grune & Stratton, 1983: 245 – 56.
- [6] **Matsuo Takashi.** Cerebral palsy: spasticity control and orthopaedics. *Soufusha, Tokyo* 2002; 64 – 74.
- [7] **Perry J.** Gait analysis system. In: *gait analysis. Normal and pathologic function.* New Jersey: SLACK; 1992: 353.
- [8] **Martz C. D.** Talipes equinus correction in cerebral palsy. *Journal of Bone and Joint Surg* [Am] 1960; 42: 769-76.
- [9] **Phelps W. M.** Long term results of orthopaedic surgery in cerebral palsy. *Journal of Bone and Joint Surgery* [Am] 1957; 39: 53 – 9.
- [10] **Pierrot A. H., Murphy O. B.** Heel cord advancement – a new approach to the spastic equinus deformity. *OCNA* 1974; 5: 117 – 26.
- [11] **Sharrard W. J. W., Bernstein S.** Equinus deformity in cerebral palsy. *Journal of Bone and Joint Surgery* [Br] 1972: 54: 272 – 6.
- [12] **Strayer L. M.** Gastrocnemius recession. *Journal of Bone and Joint Surgery* [Am] 1958; 40: 1019 – 30.
- [13] **Strecker W. B., Via M. W, Oliver S. K., Shoenecker P. L.** Heel cord advancement for treatment of equines deformity in cerebral palsy. *Journal of Pediatric Orthopaedics* [Am] 1990; 10: 105 -108.
- [14] **Throop F. B., De Rossa G. P., Reech C., Waterman S.** Correction of equinus in cerebral palsy by the Murphy procedure of tendocalcaneus advancement a preliminary communication. *Developmental Medicine and Child Neurology* 1975; 17: 182 – 5.
- [15] **Gage J. R.** The treatment of gait problems in cerebral palsy. Mac Keith Press 2004: 42 -69.
- [16] **Novachek T. F., Stout J. L., Tervo R.** Reliability and validity of the Gillette Functional Assessment Questionnaire as an outcomes measure in children with walking disabilities. *Journal of Pediatric Orthopaedics* 2000; 20: 75-81.